

ROLE OF DIACARB (ACETAZOLAMIDE) AND TIMOLOL PREMEDICATION IN PREVENTION OF CATARACT PHACOEMULSIFICATION COMPLICATIONS

Javrishvili V., Aleksidze A., Shurgaia A., Todria M.

David Tvildiani Medical University; Javrishvili Eye Clinic Oftalmij, Tbilisi, Georgia

Cataract is an age-related disease and it is one of the main causes of blindness all over the world. Cataract incidence increases with age and while its frequency is 2.9% in the population aged under 55, incidence reaches 40% in the population over 75 years [1]. Most widespread method of treatment of cataract is phacoemulsification of the opacified lens and implantation of the new, artificial lens. Phacoemulsification can be accompanied with numerous complications. The Complications are diverse and are classified in four main categories: 1. Complications associated with anesthesia, such as damage of the optic nerve (0.09-0.79%), retrobulbar hemorrhage (0.03-0.32%) and impairment of eye pupil integrity (0.009-0.13%); 2. Surgical complications, such as prolapse of vitreous body, supra-chorioid hemorrhage (0.07%), detachment of Descemet's membrane, intra-operative myosis, posterior capsule rupture (0.5-16%) and zonular dialysis; 3. Early post-surgical complications, such as anterior chamber narrowing, corneal leukoma, iris prolapse, post-surgical entophthalmia and uveitis; 4. Late post-surgical complications, such as refractive disorders and posterior capsule opacification, i.e. secondary cataract [2]. The most widespread complication is associated with the surgical factor and this is rupture of the posterior capsule [3]. In this study the emphasis is made on the prolapse of vitreous body, chamber narrowing, iris prolapse, corneal leukoma and bleeding from iris.

Diacarb is diuretic, frequently used against hypertension. Its active ingredient is Acetazolamide, it is used in Georgia, Russia, Lithuania and Latvia with the name Diacarb. Acetazolamide is carbonic anhydrase inhibitor, reduces excretion of hydrogen in kidneys and increases excretion of water, sodium, potassium and bicarbonate. It is also used for treatment of glaucoma, though regular consumption of high doses causes electrolyte imbalance.

Timolol is non-selective beta-adrenoreceptor blocker administered for treatment of increased intraocular pressure topically, in the patients with open-angle glaucoma. Active ingredient of the medicine is Timolol maleate reducing intraocular pressure due to reduction of production of the aqueous humor. It impacts systemic pressure as well. Its effect achieves maximum in 2 hours and lasts for one day. Side effects are mostly local and include conjunctival hyperemia, edema of cornea epithelium, visual blurring and itching. In the event of prolonged action ptosis can develop as well. Contraindications include cardiovascular and respiratory system disorders, especially bronchial asthma [4].

Most of the above listed pre-, intra- and post-surgery complications are associated with the variations of intraocular pressure in the course of surgical operation. Goal of our study was assessment of the role of Diacarb and Timolol in management of these complications.

Material and methods. For several months, 500 patients were specially selected for the study. They were divided into control group including 300 patients and Diacarb-Timolol group composed of 200 patients. The patients were aged from 57 to 84 years, in the control group their ages varied between 59 and 84 and in the treated group – between 57 and 81.

Control group included 183 females and 117 males while in the treated group there were 118 women and 82 men.

In the treated group the patients were prescribed single oral dose of Diacarb and single topical dose of Timolol one hour before the surgery.

Before surgery all patients were subjected to standard ophthalmologic examination. All operations were conducted by one and the same surgeon. Operations were conducted by means of phacoemulsification machine Stellaris. For anesthesia there was used tetracaine (topically) and lidocaine (retrobulbar anesthesia). Main incision was of 2.75 mm width and was made on meridian corresponding to 12 o'clock while paracentesis – 1.1 mm, at meridians corresponding to 3 and 9 o'clock, irrigation and aspiration was provided bimanually, irrigation bottle was at 100 cm height from the patient's level. Duovisc was used as main viscoelastic. After the surgery all patients were instilled antibiotics.

Results and discussion. As a result of study it was found that in control group 42 (14%) of three hundred patients had complications, while in Timolol group complications had only 10 patients (5%) of 200. Prolapse of vitreous body developed only in one patient (0.33%) of 300 in control group while in the treated group such complication was not indicated at all (0%). Rate of chamber Diacarb-Timolol). Iris prolapse was found in 12 patients (4%) of control group and 2 (1%) in Diacarb-Timolol group. Corneal opacification was identified in 10 patients (3.3%) of control group while this complication has not taken place in he treated group. Iris bleeding is a very rare complication and in this case it has developed only in 2 patients (0.67%) of control group. It should be noted that incidence of intra-surgical myosis was slightly higher in the treated group (5 patients, 2.5%), compared with the control (7 patients, 2.33%) (Fig.).

Acetazolamide is a carbonic anhydrase inhibitor and it is used for treatment of numerous diseases, including idiopathic intracranial hypertension, many types of cardiac insufficiency etc [5]. In ophthalmological practice it is used for treatment of glaucoma (in topical Diamox form). Regular, systematic administration of Acetazolamide can result in serious electrolyte imbalance and the physicians abstain from its prescribing. There were conducted numerous studies dealing with the Acetazolamide role in preventing phacoemulsification complications. Agarwal and Malik were the first (India), who showed interest to this issue and found out that Acetazolamide plays significant role in prevention of vitreous body prolapse [6]. Later Maria and Kale established that topical Acetazolamide (Diamox) has slight but not significant effect on intraocular pressure. At the same time, there was significant difference in incidence of vitreous body prolapse between control and medication groups. In case of iacarb, its risk was lower [7]. In 2014, study conducted by Hayashi, Yoshida, Sato, Manabe and Yoshimura showed that in the patients with pseudoexfoliation syndrome, oral administration of Acetazolamide significantly reduced intraocular pressure [8], especially for the first 3-5 hours. The same scientists conducted research where they compared effects of different hypotension remedies [9]. It was established that carbonic anhydrase inhibitor had the best hypotensive effect within 4-8 hours after surgery, while in 24 hours after the surgery the effects were equal.

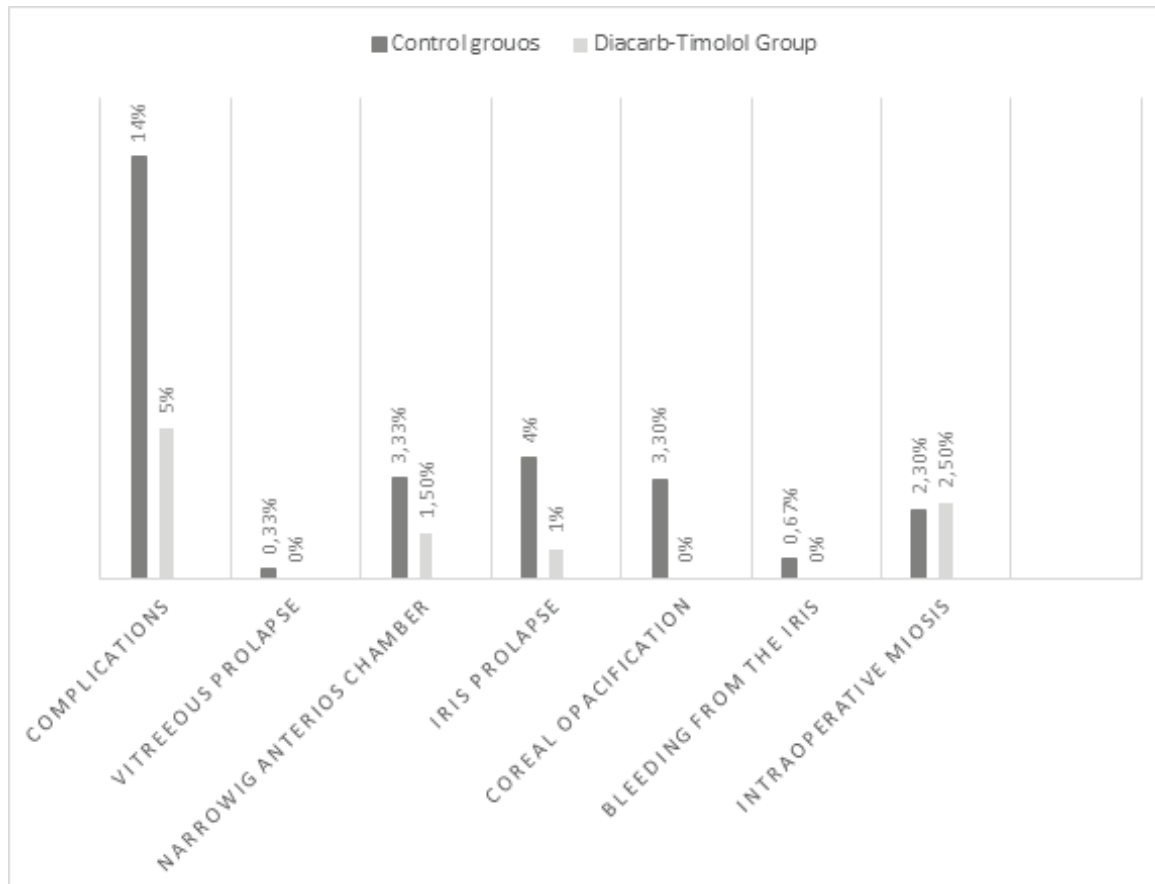


Fig. Bar chart of the percentages of complications in control and Diacarb-Timolol groups

Numerous studies were conducted about effects of Timolol and combinations of anti-glaucoma medicine combinations on post-surgical complications. In 2016, in Greece, Georgakopoulos and colleagues decided to assess the effects of beta-blockers and carbonic anhydrase on post-surgical intraocular pressure. Administration of the medicines provided desirable effect and post-surgical pressure has reduced significantly [10]. Studies conducted by Georg Rainer and colleagues in 2003 showed that combination of dorzolamide (also carbonic anhydrase inhibitor) and Timolol, within 6 to 24 hours after surgery significantly reduces the pressure, though this does not affect the pressure increases caused by viscoelastic in the course of surgery [11]. In 2001, research conducted by the same scientists compared the effects of Timolol-dorzolamide and latanoprost on post-surgical complications. It turned out that only combination of the drugs was effective [12]. Erdogan and colleagues compared combinations of Timolol with dorzolamide and Timolol with latanoprost and control group though they could not find any significant difference between three groups [13], though clinical studies conducted in 2016 in Russia confirmed that the patients who received ganfort (bimatoprost and timolol combination) had much lower intraocular pressure compared with the control [14]. Study by Borazan and colleagues showed that the effects of various medicines administered separately on post-surgical pressure did not significantly differ [15].

In September 2017, Servet Centinkaya has conducted large-scale study in Turkey, where he compared the effects of systemic Acetazolamide and topical dorzolamide-Timolol

combination on post-surgical complications and post-surgical status for 6 months [16]. No significant difference between the final results was found but, regarding numerous side effects of Acetazolamide, dorzolamide-timolol combination is recommended. Positive effect of dorzolamide-Timolol combination on post-surgical intraocular pressure in case of Steep-Trendelenburg surgery is confirmed as well [17].

All above mentioned studies make main emphasis on the post-surgical intraocular pressure while in our study we have paid great attention to such complications as vitreous body prolapse, iris prolapse, bleeding from iris, intra-surgical myosis and anterior chamber narrowing that are mostly closely associated with pressure variations in the course of surgery. Regarding close relations between the pressure and complications considered, as well as apparently positive dynamics, we should offer that further researches would substantiate the results of our study.

Conclusion. Effect of oral and topical Acetazolamide and Timolol combination in management of phacoemulsification complications is already confirmed, but these complications are mostly related to post-surgical intraocular pressure. In our study we have noticed positive dynamics in prevention of such complications as iris prolapse, iris bleeding, vitreous body prolapse and anterior chamber narrowing. To reliably substantiate the role in prevention of the mentioned complications, further researches are required in this area. More in-depth researches are required to compare effects and side effects of Acetazolamide, timolol and other preparations in intraocular pressure control.

REFERENCES

1. Barbara E. K. Klein, MD; Ronald Klein, MD; Kristine E. Lee, MS. Incidence of Age-Related Cataract The Beaver Dam Eye Study; 1998 (<https://jamanetwork.com/journals/jamaophthalmology/fullarticle/261561>)
2. Rehab Ismail and Ahmed Sallam. Complications Associated with Cataract Surgery. 2013
3. Thanigasalam Thevi, Zin Maizura, and Adinegara Lutfi Abas; The Melaka Hospital cataract complications study analysis of 12,992 eyes; 2017 (<https://www.ncbi.nlm.nih.gov/pmc/articles/PMC5369289/>)
4. <https://www.webmd.com/drugs/2/drug-11467/timolol-ophthalmic-eye/details>
5. Khashayar Farzam; Muhammad Abdullah; Acetazolamide: 2020 (<https://www.ncbi.nlm.nih.gov/books/NBK532282/>)
6. Surgery Agarwal L.P. · Malik S.R.K. Diamox (Acetazolamide) in Cataract; 1957 (<https://www.karger.com/Article/PDF/303090>)
7. DL Maria, MD Kale; Role of diamox (acetazolamide) in cataract surgery; 1970 <https://www.ijo.in/article.asp?issn=0301-4738;year=1970;volume=18;issue=3;spage=128;epage=130;aulast=Maria>
8. Ken Hayashi, MD, Motoaki Yoshida, MD, Shin-ichi Manabe, MD, Koichi Yoshimura, MD; Prophylactic Effect of Oral Acetazolamide against Intraocular Pressure Elevation after Cataract Surgery in Eyes with Glaucoma; 2017([https://www.aaojournal.org/article/S0161-6420\(16\)32432-0/pdf](https://www.aaojournal.org/article/S0161-6420(16)32432-0/pdf))
9. Ken Hayashi, Motoaki Yoshida, Tatshuhiko Sato, ShinIchi Manabe; Effect of Topical Hypotensive Medications for Preventing Intraocular Pressure Increase after Cataract Surgery in Eyes with Glaucoma; 2019 (<https://www.sciencedirect.com/science/article/pii/S0002939419301187>)
10. Constantine D Georgakopoulos 1, Olga E Makri, Panagiotis Plotas, Nikolaos Pharmakakis; Brinzolamide-timolol fixed combination for the prevention of intraocular pressure elevation after phacoemulsification (<https://pubmed.ncbi.nlm.nih.gov/23432730/>)
11. Georg Rainer 1, Rupert Menapace, Oliver Findl, Stefan Sacu, Katja Schmid, Vanessa Petternel, Barbara Kiss, Michael Georgopoulos; Effect of a fixed dorzolamide-timolol combination on intraocular pressure after small-incision cataract surgery with Viscoat (<https://pubmed.ncbi.nlm.nih.gov/14522295/>)
12. G Rainer 1, R Menapace, O Findl, V Petternel, B Kiss, M Georgopoulos; Intraindividual comparison of the effects of a fixed dorzolamide-timolol combination and latanoprost on intraocular pressure after small incision cataract surgery (<https://pubmed.ncbi.nlm.nih.gov/11377900/>)
13. Haydar Erdogan, Ayse Vural, Cengiz Caner, Mustafa Ilker Toker; Effect of latanoprost/timolol and dorzolamide/timolol on intraocular pressure after phacoemulsification surgery (https://www.researchgate.net/publication/224889363_Effect_of_latanoprosttimolol_and_dorzolamidetiimolol_on_intraocular_pressure_after_phacoemulsification_surgery)
14. Alekseev Igor B., Khatsukova Bella N., Soshina Marija M., Samokhina Nadezhda I.; Fixed combination bimatoprost-timolol in prevention of ocular hypertension after phacoemulsification of uncomplicated cataract (https://www.researchgate.net/publication/304991400_Fixed_combination_bimatoprost-timolol_in_prevention_of_ocular_hypertension_after_phacoemulsification_of_uncomplicated_cataract)
15. Mehmet Borazan 1, Aylin Karalezli, Ahmet Akman, Yonca Aydin Akova; Effect of antiglaucoma agents on postoperative intraocular pressure after cataract surgery with Viscoat
16. Stefanie Petrou Binder, MD, EyeWorld Contributing Writer; Keeping pressure down after cataract surgery; 2017 (<https://www.eyeworld.org/keeping-pressure-down-after-cataract-surgery>)
17. Bonnie Lee Molloy, Xiamei Cong, Charles Watson; Preventive Dorzolamide-Timolol for Rising Intraocular Pressure During Steep Trendelenburg Position Surgery

SUMMARY

ROLE OF DIACARB (ACETAZOLAMIDE) AND TIMOLOL PREMEDICATION IN PREVENTION OF CATARACT PHACOEMULSIFICATION COMPLICATIONS

Javrishvili V., Aleksidze A., Shurgaia A., Todria M.

David Tvildiani Medical University; Javrishvili Eye Clinic Ophthalmij, Tbilisi, Georgia

Goal - measurement of Diacarb (Acetazolamide) and Timolol effectiveness for prevention of cataract phacoemulsification complications.

Study includes 500 patients, 300 of which comprise the control group and 200 patients were administered one dose of Diacarb orally, one day before the surgery and one topical dose of oftan Timolol one hour before the surgery. The patients were observed in the course of surgery, as well as in the post-surgery period.

All patients received standard post-surgery medication, including antibiotics, steroids and lacrimal substitutes for one month. The operations were conducted by one and the same surgeon, using one and the same equipment.

Object of observation were such complications as vitreous prolapse, narrowing of anterior chamber, iris prolapse, iris bleeding, intraoperative corestenoma.

Rate of complications in the group treated with Diacarb and Timolol was much lower, compared with the control.

Pre-surgical administration of Diacarb and Timolol reduces the complication risks. More researches are required in this respect.

Keywords: Diacarb, Timolol, cataract phacoemulsification complications prevention

РЕЗЮМЕ

РОЛЬ ПРЕМЕДИКАЦИИ ДИАКАРБОМ (АЦЕТАЗОЛАМИД) И ТИМОЛОЛОМ В ПРОФИЛАКТИКЕ ОСЛОЖНЕНИЙ ФАКОЭМУЛЬСИФИКАЦИИ КАТАРАКТЫ

Джавришвили В.Г., Алексидзе А.Т., Шургая А.Т., Тодрия М.И.

Медицинский университет Давида Твилдиани; Глазная клиника Джавришвили "Офтальмидж", Тбилиси, Грузия

Цель исследования - определение эффективности диакарба (ацетазоламид) и тимолола для превенции осложнений факоемульсификации катаракты.

Исследованы 500 пациентов, 300 из них составили контрольную группу, 200 пациентов получали одноразовую пероральную дозу диакарба за один день до операции, а за час до операции - одноразовую топикальную дозу офтан тимолола.

Наблюдение велось как во время операции, так и в течение послеоперационного периода. Всем пациентам проводили стандартную послеоперационную медикаментозную терапию, включающую антибиотики, стероиды и искусственную слезу в течение одного месяца. Операции проводились одним и тем же хирургом, используя одно и то же оборудование.

Объектом наблюдения являлись такие осложнения, как

пролапс стекловидного тела, сужение передней камеры, пролапс радужной оболочки, кровотечение из радужной оболочки, интраоперационный миоз.

Показатели осложнений были значительно ниже в группе диакарба и тимолола в сравнении с контрольной группой.

Предоперационное использование диакарба и тимолола снижает риск осложнений. Необходимо проведение дальнейших исследований в этом направлении.

რეზიუმე

დიაკარბით (აცეტაზოლამიდი) და თიმოლოლით პრემედიკაციის როლი კატარაქტის ფაკოემულსიფიკაციის გართულებების პროფილაქტიკაში

ვ. ჯავრიშვილი, ა. აღუქსიძე, ა. შურგაია, მ. თოდრა

დავიდ ტვილდანიის სამედიცინო უნივერსიტეტი,
ჯავრიშვილის თვალის კლინიკა “ოფტალმიჯი”, თბილისი, საქართველო

კვლევის მიზანს წარმოადგენდა დიაკარბის (აცეტაზოლამიდი) და თიმოლოლის ეფექტურობის შეფასება კატარაქტის ფაკოემულსიფიკაციის გართულებების თავიდან აცილებაში.

გამოკვლეულია 500 პაციენტი, მათგან 300 შეადგინა საკონტროლო ჯგუფი, 200 პაციენტმა კი ძირითადი ჯგუფი. ძირითადი ჯგუფის პაციენტებს ოპერაციამდე ერთი დღით ადრე დაენიშნა დიაკარბის ერთჯერადი პერორალური, ხოლო ოპერაციამდე ერთი საათით ადრე ოფთან-თიმოლოლის ასევე ერთჯერადი ტოპიკალური დოზა. პაციენტებზე დაკვირვება განხორციელდა როგორც მთლიანი ოპერაციის მსვლელობის დროს, ასევე პოსტოპერაციულ პერიოდში. ყველა პაციენტს ჩატარდა სტანდარტული პოსტოპერაციული მედიკამენტური თერაპია, რომელიც მოიცავდა ანტი-

ბიოტიკით, სტეროიდითა და ხელოვნური ცრემლით მკურნალობას ერთი თვის განმავლობაში. ოპერაციები ჩატარდა ერთი და იგივე ქირურგის მიერ, ერთი და იგივე აღჭურვილობის გამოყენებით.

პაციენტებში დაკვირვების ობიექტს წარმოადგენდა ისეთი გართულებები, როგორცა მინისებრი სხეულის პროლაფსი, წინა საკნის დავიწროვება, ფერადი გარსის პროლაფსი, სისხლდენა ფერადი გარსიდან, ინტრაოპერაციული მიოზი.

დიაკარბისა და თიმოლოლის ჯგუფში გართულებების მაჩვენებელი მნიშვნელოვნად დაბალი იყო შედარებით საკონტროლო ჯგუფთან.

პრეოპერაციულად დიაკარბისა და თიმოლოლის გამოყენება ამცირებს გართულებების რისკს. აუცილებელია კვლევების გაგრძელება ამ მიმართულებით.

ИССЛЕДОВАНИЕ ЭФФЕКТИВНОСТИ ПРЯМОЙ РЕСТАВРАЦИИ ФРОНТАЛЬНОЙ ГРУППЫ ЗУБОВ РАЗЛИЧНЫМИ ФОТОКОМПОЗИТНЫМИ МАТЕРИАЛАМИ

Помпий А.А., Борисенко Е.Н., Керимова Т.Н., Помпий Э.С.

Луганский государственный медицинский университет, Рубежное, Украина

Патологии твердых тканей зубов достаточно часто встречаются у взрослого и детского населения Украины, при этом основными причинами потери целостности анатомической формы зубов являются кариес, травматические повреждения и некариозные поражения [1]. В различные годы доля населения страны с диагностированным кариесом составляла, по данным научной литературы, от 95 до 98%, что соответствует весьма высокому показателю распростра-

ненности заболевания [3]. Несмотря на интенсивно развивающиеся технологии в стоматологии, разработанные для эффективного восстановления дефектов коронковой части зубов, и профилактические мероприятия, направленные на предотвращение развития кариеса и некариозных поражений у детей и взрослых, эпидемиологические показатели распространенности и интенсивности этих заболеваний у населения страны продолжают ухудшаться.